



Accuracy of computer navigation in total knee arthroplasty: A prospective computed tomography-based study[☆]

Richard Hannan^a, Matthew Free^{a,*}, Varun Arora^a, Robin Harle^b, Paul Harvie^a

^a Department of Orthopaedics, Royal Hobart Hospital, 48 Liverpool St, Hobart, Tasmania, Australia, 7000

^b Department of Medical Imaging, Royal Hobart Hospital, 48 Liverpool St, Hobart, Tasmania, Australia 7000

ARTICLE INFO

Article history:

Received 7 January 2019

Revised 27 November 2019

Accepted 17 February 2020

Key Words:

Total knee arthroplasty

Computer navigation

Alignment

Validation of technology

Computed tomography

ABSTRACT

Introduction: Evidence now exists advocating the use of computer navigation in total knee arthroplasty (TKA). Despite the introduction of new navigation systems into clinical practice no evidence currently exists showing independent verification of their accuracy. The aim of this study was to validate the in vivo accuracy of the Exactech Guided Personalised Surgery (GPS) computer navigation system using a validated computed tomography (CT) measurement of alignment.

Method: Consecutive patients who underwent TKA using the GPS Navigation System at our institution were prospectively recruited. Intraoperative parameters of 3D alignment as measured by the GPS navigation system were recorded and compared against the postoperative measurements of alignment measured using the Perth CT Protocol to assess the accuracy of the GPS navigation system.

Results: 29 consecutive patients (13 male, 16 female) who underwent TKA were prospectively recruited. Overall, for all measures of 3D alignment the mean difference between intraoperatively recorded and postoperative CT-measured alignment was $1.55^\circ \pm 0.22^\circ$ (95% confidence interval). Individual measurement differences in the femoral prosthesis were: coronal alignment $1.64^\circ \pm 0.52^\circ$; flexion $2.07^\circ \pm 0.55^\circ$; rotation $1.38^\circ \pm 0.33^\circ$. Differences in the tibial prosthesis were: coronal alignment $2.03^\circ \pm 0.53^\circ$; slope $1.14^\circ \pm 0.39^\circ$. The whole limb coronal alignment difference was $2.34^\circ \pm 0.83^\circ$.

Conclusion: The Exactech GPS Navigation system is very accurate with a high concordance between intraoperative and postoperative measures of alignment and prosthesis positioning. We therefore confidently validate the system and support its continued use in clinical practice. Other navigation systems should undergo a similar validation process.

Crown Copyright © 2020 Published by Elsevier Ltd on behalf of IPPEM. All rights reserved.

1. Introduction

Computer navigation in total knee arthroplasty (TKA) aims to improve the accuracy of implant positioning and alignment. Alignment is important to the success of TKA, with numerous studies showing malalignment can lead to early wear and loosening thus worsening function and decreased survival rate [1–4]. There is now increasing evidence to suggest that computer navigation in TKA can improve implant positioning and alignment [5–8] and reduce subsequent revision rate [9].

Computer navigation in TKA was first introduced in Europe in the 1990's and to Australia in 2001 where its use has gradually increased amongst surgeons from 2.4% in 2003 to 28.6% in 2015

[☆] **Disclosures:** Financial support: none

* Corresponding author: Dr Matthew Free, Royal Hobart Hospital, 48 Liverpool St, Hobart, Tasmania, 7000.

<https://doi.org/10.1016/j.medengphy.2020.02.003>

1350-4533/Crown Copyright © 2020 Published by Elsevier Ltd on behalf of IPPEM. All rights reserved.

[10]. Although studies have shown that computer navigation increases the likelihood of a surgeon achieving accurate alignment, these studies provide little information in regards to how precisely the intraoperative alignment measurements correlate to the true post-operative alignment. Despite its increasing popularity, no computer navigation system to date has had its accuracy validated in vivo. Poorly performing prostheses are identified and flagged on the Australian Orthopaedic Association National Joint Replacement Registry (and other joint registries worldwide) [11], however this is not the case for poorly performing navigation systems.

There are numerous different computer navigation systems available. The Exactech Guided Personalised Surgery (GPS) system (Gainesville, Florida, USA) was approved for use in Australia by the Therapeutic Goods Association (TGA) in 2014 [12] as a class IIa device. It is also approved in the USA [13] as well as multiple other countries worldwide. The GPS system is an imageless infrared computer navigation system for use with the Exactech

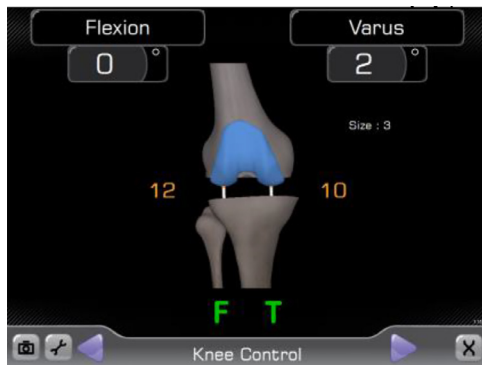

Fig. 1. Intraoperative, navigation system-derived measurement of alignment. In this example, the knee is aligned in 2° of varus and the knee is able to achieve full extension (0° flexion).

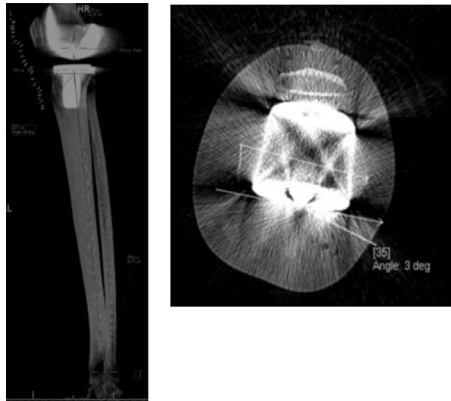


Fig. 2. CT Perth Protocol measurements of tibial component slope and femoral component rotation.

Optetrak Logic TKA. It utilises intraoperative anatomical mapping to create a working three-dimensional model of the knee. The major perceived advantage with this system over others is the use of a 4-in-1 jig that facilitates real-time, intraoperative changes of the surgical plan to be made (Fig. 1). The 4-in-1 jig acts analogous to a variable patient specific instrumentation (PSI) jig – it allows pin placement to be adjusted if new parameters are entered into the computer navigation system. Furthermore, when pinning the 4-in-1 jig in situ intraoperatively, real time movement of the jig by several degrees in three dimensions is observed numerically via the GPS computer display (Fig. 2). The system allows for correction of this, unlike a PSI jig, where subtle changes caused by suboptimal pinning technique cannot be seen nor corrected, resulting in inaccurate bone cuts.

This study aims to validate the in vivo accuracy of a TKA computer navigation system by analysing the variance between intraoperative navigation data and postoperative computed tomography (CT) alignment measurements. To the authors' knowledge, no independently performed in vivo studies validating the GPS navigation system via CT analysis have been reported.

2. Materials & methods

Formal ethics approval was obtained from the local institutional Health and Medical Human Research Ethics Committee (H0015178). The study was conducted in a high-volume arthroplasty centre within a university tertiary referral hospital. Consecutive patients scheduled to undergo primary TKA surgery at the institution were prospectively recruited. To participate in the study patients were consented to have a post-operative CT scan using the

Perth CT protocol. The only exclusion criterion was a refusal of patient consent or inability (for whatever reason) to agree to postoperative CT scanning.

All patients in the study underwent a fully cemented, posterior stabilised Optetrak Logic TKA with patella resurfacing using the Exactech computer navigation (Guided Personalised Surgery) system. All procedures were performed by the senior author or by a trainee under his direct supervision. Previous formal training had been undertaken using the navigation system with over 30 cases performed prior to the study to avoid any early learning curve issues [14]. A medial parapatellar approach and posterior condylar axis (PCA) referencing were used in all cases (refer to Appendix 1 for further details on intraoperative navigation). Intraoperatively all measures of 3D femoral and tibial alignment parameters and the whole limb mechanical axis (as expressed by the GPS system) were recorded (Fig. 1).

Postoperatively patients underwent a CT scan using a modified version of the Perth CT protocol [15]. The Perth CT protocol is a validated method of accurately assessing the alignment and rotation of TKA components. The lower limb is scanned from acetabular roof to talar dome and images are reformatted to produce coronal, sagittal and axial images. From these reformatted images the mechanical axes of the femur, tibia and whole lower limb are established. The coronal and sagittal alignment of the prostheses are then described relative to these axes. The distal femoral transepicondylar axis (TEA) is measured and the rotation of the femoral component is calculated relative to this (Fig. 2). The modification to the Perth CT protocol that our study required was to specifically measure the femoral and tibial prostheses coronal alignment relative to the mechanical axes of the femur and tibia, respectively. It was also used to measure the whole limb coronal alignment. The original CT Perth protocol describes the coronal alignment of each prosthesis in relation to the mechanical axis of the entire lower limb – a different measurement to that produced by computer navigation systems in TKA. Our modification allows comparison between the results from the GPS navigation system and the postoperative CT scan.

The CT scans were reported by a senior consultant radiologist who was blinded to the intraoperative findings. Intraoperative measurements of alignment, as recorded by the GPS system, were then compared with CT-derived measurements for each patient. The absolute difference between the individual navigation system-reported and CT-measured result was calculated. From these results the mean error (both overall and for each parameter) and 95% confidence intervals (CI) were determined. Statistical software used was Microsoft Excel for Mac (Version 15.28, Microsoft, Redmond, Washington USA).

3. Results

30 consecutive patients were prospectively recruited. No patients refused to participate. One patient was excluded because trackers loosened intraoperatively requiring conversion to a conventional technique. One patient's results could not be fully analysed because the saved GPS data regarding his femoral component coronal alignment and flexion was corrupted.

Of 29 patients, 13 were male and 16 female, with a mean age of 67.8 years (range 53–85 years). The primary operator was a supervised trainee in 13 cases and an orthopaedic consultant in 16 cases.

The overall mean difference in navigation-reported and CT-measured alignment parameters was 1.55° (1.33°–1.77° (95% CI)). A summary of the results is given in Table 1.

Table 1
Results.

Measurement	Mean difference (degrees) (95% confidence intervals)
Femoral prosthesis varus/valgus	1.64° (1.12°–2.16°)
Femoral prosthesis flexion	2.07° (1.52°–2.62°)
Femoral prosthesis rotation	1.38° (1.05°–1.71°)
Tibial prosthesis varus/valgus	2.03° (1.50°–2.56°)
Tibial slope	1.14° (0.75°–1.53°)
Whole limb coronal alignment	2.34° (1.51°–3.17°)
Combined overall measurement	1.55° (1.33°–1.77°)

4. Discussion

The improved accuracy in implant positioning that computer navigation allows in TKA surgery has led to its increased use in Australia and worldwide. Subsequently this has also led to an increase in the number of computer navigation systems being available for use [9], as well as the development of new technology such as electromagnetic, accelerometer and handheld systems [16,17]. Although there is a large amount of literature published regarding computer navigation in TKA there is very little focus on the inherent accuracy of the individual navigation system being used. To the authors' knowledge, no current studies exist with post-operative CT validation of the in vivo accuracy of any computer navigation system in TKA.

In Australia, TGA approval of surgical computer navigation systems are as class IIa devices. This category of medical devices is defined as low to medium risk that does not require significant regulation or scrutiny. Other similarly categorised IIa devices include intravenous line tubing and catheters [18]. In the USA the Food and Drug Administration process, known as 510(k), allows new devices to be cleared for use without evidence if they are 'substantially equivalent' to an already marketed device [19]. This is applied to the computer navigation system used in our study [13] as well as to the majority of new computer navigation systems. Given this low level of regulation of computer navigation systems in TKA, surgeons need to be confident that the data they are seeing intra-operatively is a true representation of what is present *in vivo*.

Other studies exist that compare intraoperative navigation data to postoperative long leg radiographs [20–24]. This approach is limited and does not validate the accuracy of these systems. CT imaging is required to assess a computer navigation system's accuracy in rotational and sagittal parameters. Postoperative CT for alignment measurement in TKA is more accurate than plain radiographs as well as having better intra- and inter-observer reliability [25]. Many of these studies [21–23] use a different statistical method in the interpretation of their data to ours, analysing the difference between the mean navigation derived and mean radiograph derived measurements, instead of calculating the mean of the (absolute) differences. This would lead to differing results when compared to our methodology and may overestimate the accuracy of a system.

We found only one other study in the literature with a similar methodology to ours. Dahabreh et al. [26] retrospectively compared the degree of mismatch between the intraoperative navigation data from two TKA navigation systems, the ORTHOsoft system (Zimmer Inc, Warsaw, USA) and the Precision system (Stryker Orthopaedics, Kalamazoo, USA), using the CT Perth Protocol. Their (combined) results show a high level of in vivo accuracy of both systems, equivalent to our results with the GPS system. Each system's individual results for mean error were not published, however, meaning that the published paper does not specifically validate either system. Furthermore, while Dahabreh's study utilises the CT Perth Protocol they are not using a modified version and are therefore not measuring the same parameter

that the navigation system records. A strength of our study is that through the use of a modified CT Perth Protocol the measurements of the scan match the measurements being produced by our navigation system, therefore significantly increasing the accuracy of these comparisons. A study by Abdel et al. [27] used long leg radiographs in conjunction with knee CT to assess the accuracy of the Brainlab system (Brainlab, Feldkirchen, Germany). However, this study aimed to evaluate the system's accuracy in assessing PSI jig placement in TKA, not to validate the Brainlab system's use in computer navigated TKA. It also did not use absolute values when calculating the mean difference, making it difficult to compare the results with ours.

Similar studies have been performed assessing the accuracy of robotic-assisted or patient-specific systems for other procedures. Cobb et al. [28] used CT to evaluate the accuracy of 13 robotic-assisted unicompartmental knee arthroplasty operations and found all patients achieved tibiofemoral alignment in the coronal plane within 2° of the planned position. Verborgt et al. [29] assessed the accuracy of patient-specific instrumentation (PSI) in reverse shoulder arthroplasty and found PSI allowed the surgeon to accurately execute the preoperative plan, with the mean deviation in base-plate version 4.4° from the preoperative plan.

There are several potential reasons why intraoperative and postoperative measurements of alignment may differ. The final navigation system data is reported from bone cut surfaces prior to prosthesis insertion. Inaccurate placement of the prosthesis components via poor cementation or an asymmetric mantle, for example, may lead to a measured difference postoperatively that is surgically created and not a navigation system error [30]. In addition, the intra-operative measurements are taken when the patient is under anaesthetic and the knee wound is open. This may cause differences in muscle tone and soft tissue tension around the knee and affect the whole limb coronal alignment. CT measurements in our study were taken with patients supine (i.e. non-weight bearing) which may also introduce errors in the calculation of the whole limb coronal alignment [31]. Care was taken to ensure that the CT was performed in full extension as any flexion may lead to abnormal alignment or rotational mismatch [32]. In regards to measurement of femoral prosthesis rotation this relies on assumptions about the patient's normal anatomy. In our study, the posterior condylar axis (PCA) was used intraoperatively as a reference for femoral component rotation. On postoperative CT scans this is not possible as the posterior femoral condyles have been removed and instead the transepicondylar axis (TEA) was used. In most patients the TEA is 3° externally rotated to the PCA [33] and this was taken into account in calculations. This assumption would not be true for all patients, however, which may create inaccuracies when measuring femoral component rotation. Despite this, our study found measurements of femoral component rotation to be accurate (mean difference 1.38°). A review by Gromov et al. [34] suggested that the femoral component should be placed within 2–5° of external rotation in relation to the sTEA. With most surgeons aiming for the femoral component to be 3° externally rotated, the mean difference between intraoperative and postoperative values in our study would still enable surgeons to be within this target range.

There are several limitations to our study. Our study used numerous surgeons to perform the operation, albeit under the supervision of the senior surgeon. Slight variations in surgical technique may create inaccuracies in intra-operative measurements. However, with the aim of the study simply being to validate the accuracy of the navigation system, our findings demonstrating excellent accuracy of the navigation system are robust to the potential methodological weakness through the use of multiple surgeons. Another potential limitation of our study is the measurement process utilised. As with any radiographical measurement, the measurements determined from the post-operative CT scans

may be affected by intra- and inter-reporter reliability, and this is something we have not accounted for in our study [35]. Despite this, the CT Perth Protocol has a high reported intra-reporter reliability [15], and the use of a single consultant radiologist reporting all of the CT scans in the study minimises potential inter-reporter differences. Our study did not report on final prosthesis position. This was a deliberate decision from the authors. As previously stated, the goal of our study was to assess the accuracy of the computer navigation system and its software. Prosthesis position in computer navigated TKA has been extensively studied previously and it can be affected by factors outside of the accuracy of the navigation system, such as surgeon error in performing cuts or implantation of the prosthesis itself. Therefore, this study validates the use of the GPS navigation system only, not the associated TKA and instrumentation. By controlling for these factors we were able to accurately assess and validate the accuracy of the navigation system using a small sample size and easily reproducible method. Lastly, whilst the described measurements of alignment in our study (varus-valgus, flexion-extension, rotation) are the most common and accessible method of analysing TKA accuracy, this is not a true representation of overall three dimensional orientation, and ultimately intraoperative and postoperative software enabling comparison between three dimensional reconstructions would add further accuracy to studies of alignment in TKA.

5. Conclusion

This study shows that the Exactech computer navigation system in TKA is accurate in predicting postoperative alignment and

prosthesis position. Intraoperative measures of alignment were found to be within an overall mean of 1.55° when compared to measures on postoperative CT. This study is the first to accurately assess the precision of a computer navigation system in TKA via CT analysis and supports its continued use in clinical practice. Given the high level of precision and ease of reproducibility allowed by our methodology we recommend that all new TKA computer navigation systems be similarly validated.

Declaration of Competing Interest

none

Acknowledgements

None

Funding

None

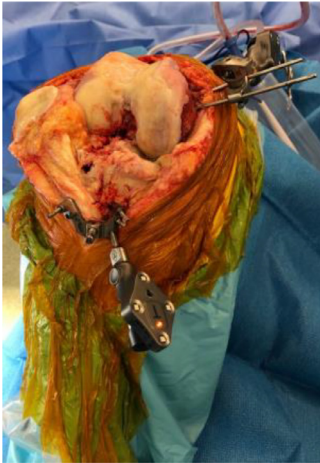Ethical approval

Granted (please refer to author declarations submission)

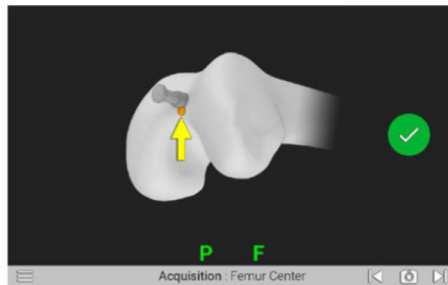
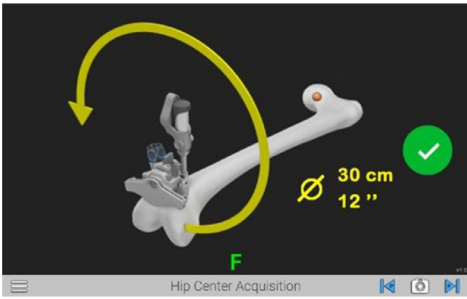
Appendix 1

Intraoperative navigation steps.

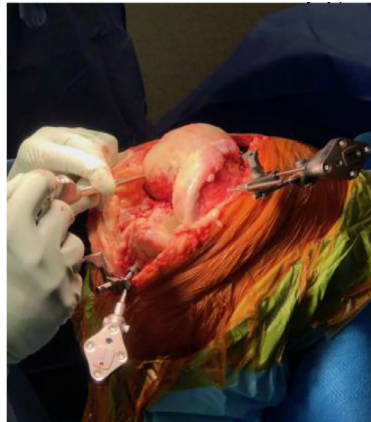
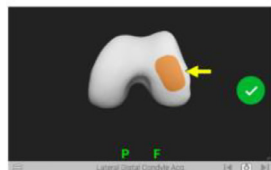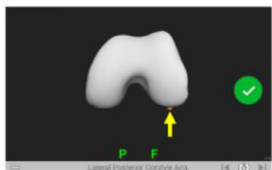
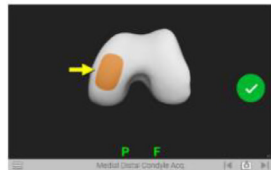
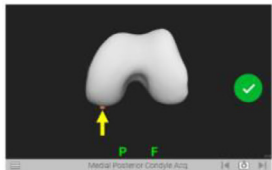
A single pin is placed at the medial femoral condyle ridge and then a guide is used to place a second pin. A tibial extra-medullary alignment guide is used to position two proximal tibia pins. The infrared navigation trackers (F tracker and T tracker) are then attached.



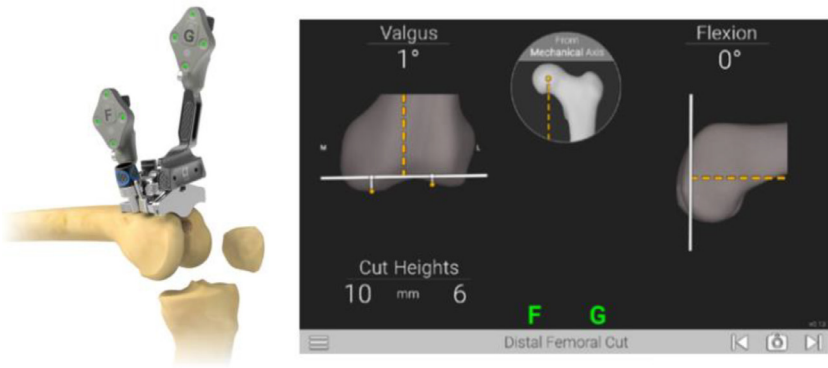
Circular motion of the hip is used to acquire the hip centre and knee centre and to define the mechanical axis of the femur.



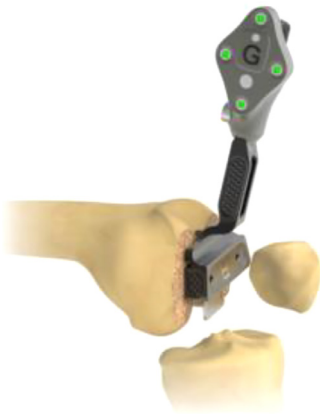A probe is then used to define specific anatomical landmarks of the femur and tibia with the navigation trackers attached (lateral femoral condyle landmark acquisition pictured below).



The G tracker is attached and the distal femoral cut screen is displayed. Adjustments are made to the guide to the desired distal femur resection.



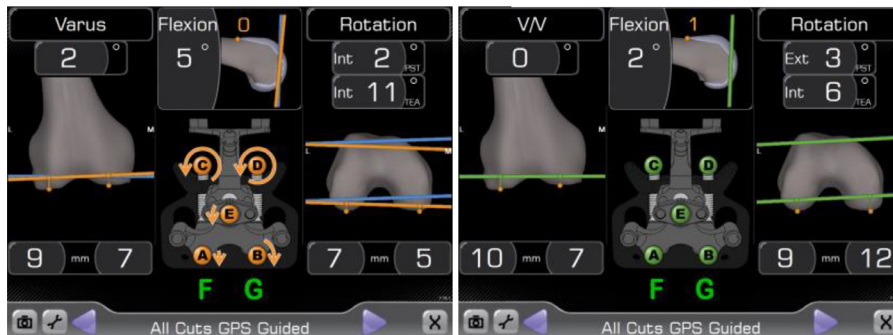
The distal femur resection can be verified by placing the G tracker on the cut surface.



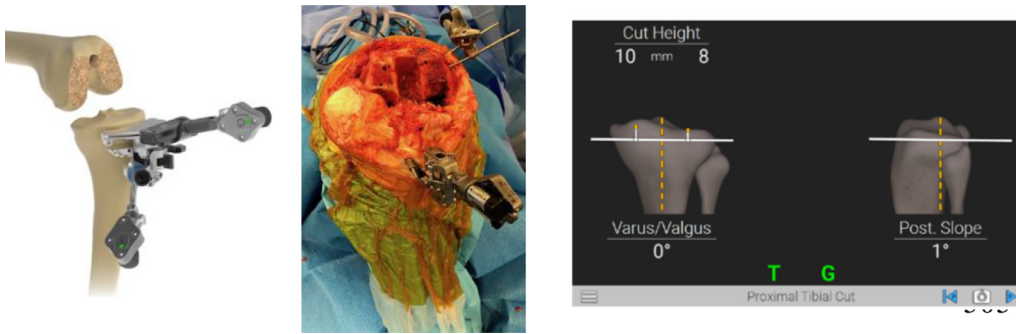
The 4-in-1 jig is attached to complete distal femur resections. Photograph below of the GPS system's 4-in-1 jig and its positioning intra-operatively.



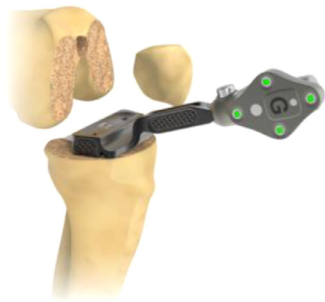Screenshots of the GPS system while the 4-in-1 jig is adjusted to achieve the desired orientation and alignment. Left showing need for further adjustment, right showing correct position.



The tibial resection guide with the attached T tracker and G tracker is pinned to the proximal tibia and the proximal tibia cut screen is displayed. Adjustments are made to the guide to the desired proximal tibia resection.



The proximal tibia resection can be verified by placing the G tracker on the cut surface.



References

- [1] Ritter MA, Davis KE, Meding JB, Pierson JL, Berend ME, Malinzak RA. The effect of alignment and BMI on failure of total knee replacement. *JBJS* 2011;93(September 7 (17)):1588–96.
- [2] Fang DM, Ritter MA, Davis KE. Coronal alignment in total knee arthroplasty: just how important is it? *J Arthroplasty* 2009;24(September 1 (6)):39–43.
- [3] Berend ME, Ritter MA, Meding JB, Faris PM, Keating EM, Redelman R, et al. The Chetranjan Ranawat Award: tibial component failure mechanisms in total knee arthroplasty. *Clin Orthop Relat Res* 2004;428(November 1):26–34.
- [4] Ritter MA, Faris PM, Keating EM, Meding JB. Postoperative alignment of total knee replacement. Its effect on survival. *Clin. Orthop Relat Res* 1994(Febuary (299)):153–6.
- [5] Miyasaka T, Kurosaka D, Saito M, Omori T, Ikeda R, Marumo K. Accuracy of computed tomography-based navigation-assisted total knee arthroplasty: outlier analysis. *J Arthroplasty* 2017;32:47–52. doi:10.1016/j.arth.2016.05.069.
- [6] Zamora LA, Humphreys KJ, Watt AM, Forel D, Cameron AL. Systematic review of computer-navigated total knee arthroplasty. *ANZ J Surg* 2013;83(January (1–2)):22–30.
- [7] Cheng T, Zhao S, Peng X, Zhang X. Does computer-assisted surgery improve postoperative leg alignment and implant positioning following total knee arthroplasty? A meta-analysis of randomized controlled trials? *Knee Surg, Sports Traumatol Arthrosc* 2012;20(July 1 (7)):1307–22.
- [8] Chin PL, Yang KY, Yeo SJ, Lo NN. Randomized control trial comparing radiographic total knee arthroplasty implant placement using computer navigation versus conventional technique. *J Arthroplasty* 2005;20(August 1 (5)):618–26.
- [9] De Steiger RN, Liu YL, Graves SE. Computer navigation for total knee arthroplasty reduces revision rate for patients less than sixty-five years of age. *JBJS* 2015;97(April 15 (8)):635–42.
- [10] Australian Orthopaedic Association National Joint Replacement Registry. Annual Report 2015. <https://aoanjr.sahmri.com/documents/10180/275066/Hip%2C%20Knee%20%26%20Shoulder%20Arthroplasty> (Accessed 17 August 2018).
- [11] Steiger RN, Miller LN, Davidson DC, Ryan P, Graves SE. Joint registry approach for identification of outlier prostheses. *Acta Orthop* 2013;84(August 1 (4)):348–52.
- [12] Therapeutic Goods Administration. Exactech Australia – GPS System – Robot, surgical, navigation unit 2014. [https://www.ebs.tga.gov.au/servlet/xmlmillr67dbid=ebs/PublicHTML/pdfStore.nsf&docid=DD0CFCB944A2E85ECA257E4B004234F2&agid=\(PrintDetailsPublic\)&actionid=1%20\(accessed%20January%2012,%202017\)](https://www.ebs.tga.gov.au/servlet/xmlmillr67dbid=ebs/PublicHTML/pdfStore.nsf&docid=DD0CFCB944A2E85ECA257E4B004234F2&agid=(PrintDetailsPublic)&actionid=1%20(accessed%20January%2012,%202017)). (Accessed 17 August 2018).
- [13] Food and Drug Administration. 510(k) Summary Blue Navigation System 2010. https://www.accessdata.fda.gov/cdrh_docs/pdf10/K100742.pdf (Accessed 17 August 2018).
- [14] Jenny JY, Miehlik RK, Giurea A. Learning curve in navigated total knee replacement. a multi-centre study comparing experienced and beginner centres. *Knee* 2008;15(March 1 (2)):80–4.
- [15] Chauhan SK, Clark GW, Lloyd S, Scott RG, Bredahl W, Sikorski JM. Computer-assisted total knee replacement: a controlled cadaver study using a multi-parameter quantitative CT assessment of alignment (the Perth CT protocol). *The Journal of bone and joint surgery. British volume*. 2004;86(August (6)):818–23.
- [16] Lionberger DR, Weise J, Ho DM, Haddad JL. How does electromagnetic navigation stack up against infrared navigation in minimally invasive total knee arthroplasties? *J Arthroplasty* 2008;23(June 1 (4)):573–80.
- [17] Huang EH, Copp SN, Bugbee WD. Accuracy of a handheld accelerometer-based navigation system for femoral and tibial resection in total knee arthroplasty. *J Arthroplasty* 2015;30(November 1 (11)):1906–10.
- [18] Therapeutic Goods Administration. The regulation of medical devices 2011. <https://www.tga.gov.au/behind-news/regulation-medical-devices> (Accessed 18 August 2018).
- [19] Curfman GD, Redberg RF. Medical devices—balancing regulation and innovation. *N Eng J Med* 2011;365(September 15 (11)):975–7.
- [20] Dixel J, Kirschner S, Günther KP, Lützner J. Agreement between radiological and computer navigation measurement of lower limb alignment. *Knee Surg, Sports Traumatol Arthrosc* 2014;22(November 1 (11)):2721–7.
- [21] Carli A, Ahmed Aoude AR, Matache B, Antoniou J, Zukor DJ. Inconsistencies between navigation data and radiographs in total knee arthroplasty are system-dependent and affect coronal alignment. *Can J Surg* 2014;57(October 5(5)):305.
- [22] Seo SS, Seo JH, Sohn MW, Kim YJ. Differences in measurement of lower limb alignment among different registration methods of navigation and radiographs in TKA using the OrthoPilot system. *Orthopedics* 2012;35(October 1 (10)):50–5.
- [23] Chung BJ, Dileep I, Chang CB, Kang YG, Park YB, Kim TK. Novel approach to reducing discrepancies in radiographic and navigational limb alignments in computer-assisted TKA. *Orthopedics* 2010;33(October 1 (10)):62–7.
- [24] Yaffe MA, Koo SS, Stulberg SD. Radiographic and navigation measurements of TKA limb alignment do not correlate. *Clin Orthop Relat Res* 2008;466(November 1 (11)):2736–44.
- [25] Hirschmann MT, Konala P, Amsler F, Iranpour F, Friederich NF, Cobb JP. The position and orientation of total knee replacement components: a comparison of conventional radiographs, transverse 2D-CT slices and 3D-CT reconstruction. *J Bone And Joint Surg. Br Vol.* 2011;93(May (5)):629–33.
- [26] Dahabreh Z, Scholes CJ, Giuffre B, Coolican MR, Parker DA. Lack of agreement between computer navigation and post-operative 2-dimensional computed tomography (CT) measurements for component and limb alignment in total knee arthroplasty (TKA). *Knee* 2016;23(January 1 (1)):137–43.

- [27] Abdel MP, von Roth P, Hommel H, Perka C, Pfltzner T. Intraoperative navigation of patient-specific instrumentation does not predict final implant position. *J Arthroplasty* 2015;30(April 1 4):564–6.
- [28] Cobb J, Henckel J, Gomes P, Harris S, Jakopec M, Rodriquez F, et al. Hands-on robotic unicompartmental knee replacement: a prospective, randomised controlled study of the acrobat system. *J Bone and Joint Surg. Br Vol.* 2006;88(February (2)):188–97.
- [29] Verborgt O, Hachem A, Eid K, Vuylsteke K, Ferrand M, Hardy P. Accuracy of patient-specific guided implanon of the glenoid component in reversed shoulder arthroplasty. *Orthop & Traumatol* 2018;104(October (6)):767–72.
- [30] Catani F, Biasca N, Ensini A, Leardini A, Bianchi L, Digennaro V, Giannini S. Alignment deviation between bone resection and final implant positioning in computer-navigated total knee arthroplasty. *JBJS* 2008;90(April 1 (4)):765–71.
- [31] Kendoff D, Board TN, Citak M, Gardner MJ, Hankemeier S, Ostermeier S, et al. Navigated lower limb axis measurements: influence of mechanical weight-bearing simulation. *J Orthop Res* 2008;26(April (4)):553–61.
- [32] Lonner JH, Laird MT, Stuchin SA. Effect of rotation and knee flexion on radiographic alignment in total knee arthroplasties. *Clin Orthop Relat Res* 1996;331(October 1):102–6.
- [33] Whiteside LA. Ligament balancing in revision total knee arthroplasty. *Clin Orthop Relat Res* 2004;423(June 1):178–85.
- [34] Gromov K, Korchii M, Thomsen MG, Husted H, Troeslen A. What is the optimal alignment of the tibial and femoral components in knee arthroplasty? An overview of the literature. *Acta Orthop* 2014;85(September (5)):480–7.
- [35] Victor J, Van Doninck D, Labey L, Innocenti B, Parizel PM, Bellemans J. How precise can bony landmarks be determined on a CT scan of the knee? *Knee* 2009;16(October 1 (5)):358–65.